

REFERENCES

- (1) Doak, G. O., *Jour. A. Ph. A.*, 29 (1940), 108.
- (2) Method to be published elsewhere.
- (3) Hubbard, Donald M., *Ind. Eng. Chem., Anal. Ed.*, 2 (1939), 343.
- (4) Von Oettingen, W. F., *Physiol. Rev.*, 10 (1930), 221.
- (5) Hanzlik, P. J., Lehman, A. J., and Richardson, O. P., *J. Pharmacol.*, 62 (1938), 404.

Effect of Fresh *Alæ Vera* Jelly in the Treatment of Third-Degree Roentgen Reactions on White Rats*

A Preliminary Report

By Tom D. Rowe†

So far as is known, there is no proven curative treatment for third-degree roentgen reactions. In March 1935, Drs. C. E. and Creston Collins called attention to an apparently successful treatment of X-ray reactions by the use of fresh *Alæ vera* leaf (1). Since that time various medical journals have carried articles by physicians reporting the effectiveness of this leaf in treating such burns (2, 3, 4, 5, 6, 7, 8, 9, 10). These reports have been sufficiently promising to indicate that this leaf possesses curative properties. However, all of the work has been done on individual cases, and no reports have been made on experimental work in which controls were used. It appeared, therefore, that before *Alæ vera* could be given full credit for beneficial effects, controlled experimental work should be done.

With this in mind, Dr. C. A. Pohle, professor of radiology, University of Wisconsin, was consulted as to the animals to use and what section of the animals was best suited for the study of irradiation reactions. He suggested the skin of the back of white rats. The first few months of work were entirely experimental, and were directed toward determining what technique and dosage of

roentgen rays to use. Twenty-four rats were used for this purpose. At the conclusion of this work, the actual problem was begun.

EXPERIMENTAL

Dr. F. B. Mandeville, professor of radiology at the Medical College of Virginia, cooperated in all X-ray treatments and supervised their administration. In carrying out this problem, the following procedure was employed: First, the rats were anesthetized by intraperitoneal injection of pentobarbital. The hair on the back was then removed with scissors and the rats irradiated individually. During irradiation, each rat was entirely covered with lead foil except for two areas on the back. These areas were 2 cm. square and approximately 2½ cm. apart. The rats were given a total of 4000 r., using no filter with 100 kilovolts, 5 milliamperes at a distance of 22.5 cm. They were given the 4000 r. in two doses, 2000 r. one week and 2000 r. a week later. Administration of 4000 r. in a single dose frequently caused death. Using the above factors, 300 r. is the dose which will produce threshold erythema on the average human adult.

Treatment was administered to the rats in groups of eight. Three weeks after the first 2000 r. had been given, each rat showed severe, third-degree X-ray reactions on each of the exposed areas. Photographs were taken at this time and treatment with *Alæ vera* was begun (Fig. 1).

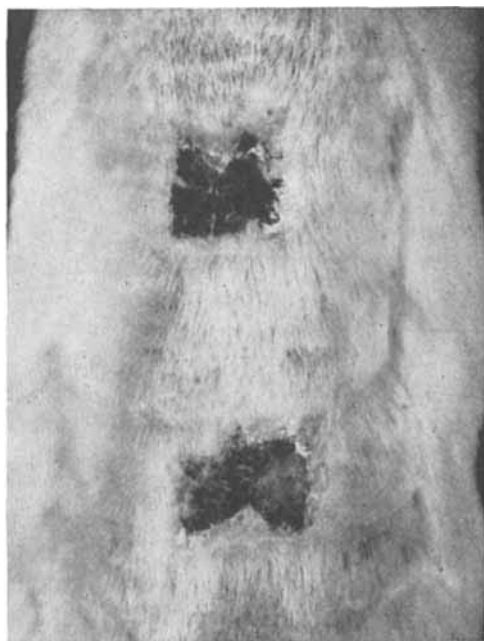


Fig. 1.—Typical Irradiated Areas at Beginning of Treatment.

One irradiated area was used as a control, receiving no treatment other than two applications daily of cotton packs saturated with normal saline

* Presented before the Scientific Section, AMERICAN PHARMACEUTICAL ASSOCIATION, Richmond meeting, 1940.

The work reported on in this paper was partly financed by grants from the Virginia Academy of Science and the Medical College of Virginia Research Fund.

† Assistant Professor of Pharmacy, School of Pharmacy, Medical College of Virginia, Richmond, Virginia.

solution. The other area was treated twice daily with about 1 Gm. of fresh aloe jell, the gelatinous material found inside the leaf. This was applied for four hours at a time and the area was washed with normal saline before applying fresh jell. This procedure was continued for fourteen days on each of the rats in a group. Two days after conclusion of this treatment the animals were photographed, thus giving a series of "before and after" pictures. During treatment, and from four to six weeks afterward, they were kept in separate cages. At the end of that time they were grouped together and reserved for further observation. The jell was kept in place on the rats by means of jackets and collars devised for this purpose. These are shown in Fig. 2.

Forty rats were irradiated in the manner described above. Five of these were used as check controls, receiving no jell or saline treatment. Of the 40 rats irradiated, 31 lived until conclusion of the jell treatment. Three of these were in the check-control group. Thus, 28 rats were treated with the jell. The five groups gave results shown in the following table:

By combining all of the results given in Columns I and II, it is shown that 14 areas, or 50% of those treated with the jell, showed increased rate of heal-

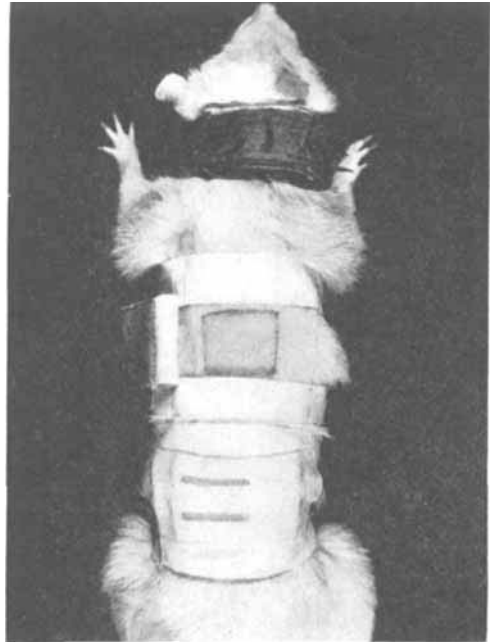


Fig. 2.—Collar and Jacket Used to Apply Jell.

	I	II	III	IV	V
	Improvement ^a with Jell Definite	with Jell Slight	Both Areas Alike at End of Treatment	Improvement with Saline Slight	Saline Definite
Group No. 1 3 rats	2	0	1	0	0
Group No. 2 6 rats	0	1	1	1	3
Group No. 3 8 rats	3	1	4	0	0
Group No. 4 4 rats	2	1	0	0	1
Group No. 5 7 rats	3	1	2	0	1

^a Improvement based on comparison of the two irradiated areas on the rat.

ing. Of these, 10 areas, or 35.72%, showed nearly complete healing at the conclusion of treatment. This number is twice that which showed marked improvement with saline.

The results on all five columns can be interpreted by statistical means. Using +2 for each animal in Column I, +1 for Column II, 0 for Column III, -1 for Column IV and -2 for Column V, it is shown that the probability that there is benefit with the jell is 9/10. This is not considered certainty.¹

It will be noted that Group No. 2 gave results reverse to the other four groups. There is no explanation for this.

Of the three control animals which lived, two showed no improvement on either area. On the third, both areas were nearly healed two weeks after the last administration of X-ray.

¹ Statistical interpretation done by Mr. J. A. Bradford, Research Laboratory, American Tobacco Company, Richmond, Va.

After conclusion of the jell treatment, the rats were examined once a month. At three and a half months scabs 1 cm. square had appeared on the saline-treated areas of three of the rats. These did not increase in size.

One year after the last group had been treated, 13 of the rats were living. One of these was from the check control group. All the others had been treated with the jell. Of these, both areas showed complete macroscopic healing on nine rats. A small (0.5 x 0.5 cm.) scab was present on the untreated area of one rat, the treated area being completely healed. A pronounced scab (1½ cm. x 1½ cm.) was present on the treated area of one rat, the untreated area being completely healed. The three animals which were previously mentioned as showing a recurrence of injury at 3½ months were not alive when the examination was made at the end of one year.

When possible, the dead rats were turned over to the pathology department for histopathological ex-

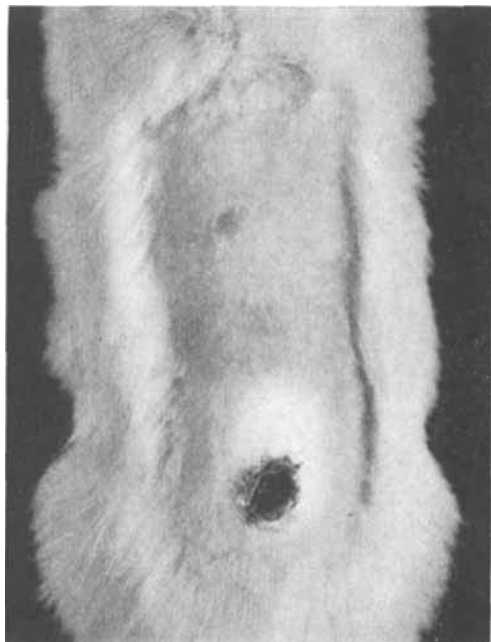


Fig. 3.—Typical Case of Definite Improvement.

aminations. These were done by Dr. George Z. Williams, associate professor of pathology, Medical College of Virginia. He examined 14 rats. Five of these died during different periods of treatment. Nine died at periods ranging from one week to twelve months after treatment. He made the following report on his examinations:

1. Animals which died during treatment: "No qualitative variations could be found to distinguish the treated and untreated irradiated rats."

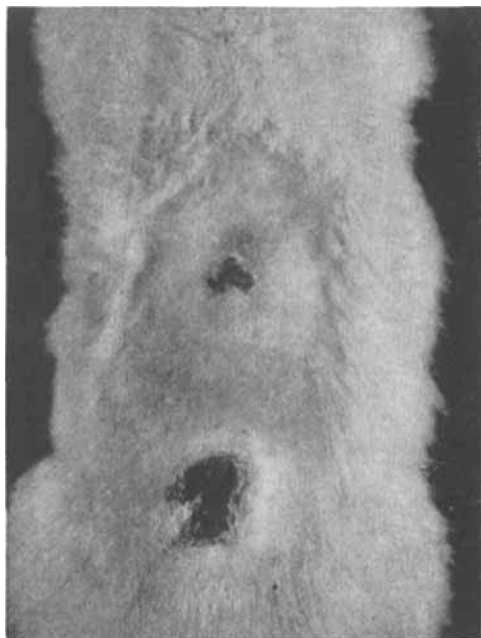


Fig. 4.—Typical Case of Slight Improvement.

2. Animals which died after treatment: "The healed scars were different histologically only in degree of fibrosis and atrophy of the skin, no qualitative changes being discernible between anterior and posterior areas."

SUMMARY

To date, no definite conclusions have been drawn from the work because: (1) too few animals have received treatment; (2) the 14-day period of treatment is too short a time on which to base final conclusions.

From the results obtained, fresh *Alæ vera* jell shows some promise of being of value in the treatment of X-ray reactions. Plans have been made to continue this problem along the lines already pursued. A larger number of animals is to be treated for a longer period of time.

REFERENCES

- (1) Collins, C. E., and Collins, C., *Am. J. Roentgenol. Radium Therapy*, 33 (1935), 396.
- (2) Collins, C. E., *Radiol. Rev. and Chicago Med. Rec.*, 57 (1935), 137.
- (3) Wright, C. S., *J. Am. Med. Assoc.*, 106 (1936), 1363.
- (4) Discussion (several physicians refer to *Alæ vera*), *Arch. Dermatol. and Syphilol.*, 33 (1937), 593.
- (5) Jenkins, G. L., and Waldron, C. H., *Amer. Professional Pharmacist*, 3 (1937), 15. A review of literature on burn treatment includes *Alæ vera*.
- (6) Loveman, A. B., *Arch. Dermatol. and Syphilol.*, 33 (1937), 838.
- (7) Mandeville, Fred B., *South. Med. & Surgery*, 100 (1938), 69.
- (8) McKee, George M., "X-rays and Radium in the Treatment of Diseases of the Skin," 3d Edition, Lea & Febiger, Philadelphia (1938), pages 319, 320.
- (9) Fine, Archie, and Brown, Samuel, *Radiology*, 31 (1938), 735.
- (10) Mandeville, Fred B., *Ibid.*, 32 (1939), 598.

Red Squill, VII. Influence of Altitude upon Toxicity to Albino Rats*

By Justus C. Ward, H. J. Spencer, D. Glen Crabtree and F. E. Garlough

Powdered red squill (*Urginea maritima*) is used as a toxic agent for the control of rats in all parts of the country, and since it is employed as a crude powder and the

* From the Control Methods Research Laboratory, Bureau of Biological Survey, U. S. Department of the Interior.